

VERTEBRAL OSTEOMYELITIS WITH MEDULLARY COMPRESSION IN CHAMOIS

Bassano B.*, Peracino V.*, Bossi D.**, Schröder C.***, Guarda F.*** & A. Perrone****

*Centro Studi Veterinari della Fauna Alpina, P.N.Gran Paradiso, Torino, 10123 - Italy

** U.S.S.L. n. 49, Borgosesia, Vercelli - Italy

*** Dipartimento di Patologia Animale, Facoltà di Medicina Veterinaria, Torino, 10126 - Italy

**** Centro Ricerche in Ecologia Applicata, Torino, 10126 - Italy

Riassunto - Vengono presentati due casi di osteomielite vertebrale con compressione midollare in camosci provenienti dalla provincia di Vercelli (Arco alpino occidentale italiano). Entrambi i soggetti, dal punto di vista clinico, presentavano paraplegia agli arti posteriori, che ne ha consentito la cattura a mano. I soggetti si sono rivelati affetti da Pseudo-tubercolosi (*Corynebacterium pseudotuberculosis*): la diagnosi eziologica è stata possibile sia per i rilievi anatomo-patologici, sia per il risultato dell'esame batteriologico. I casi descritti appaiono di una certa rilevanza in quanto, mentre l'infezione pseudo-tubercolare è piuttosto frequente non solo negli ovini e nei caprini ma anche nei ruminanti selvatici, la localizzazione dell'agente patogeno al tessuto osseo si può considerare del tutto eccezionale.

IBEX J.M.E. 1:31-33

1. Introduction

The bone pathology of free-roaming wild ruminants, described to date is composed almost exclusively of traumatic lesions (Olt & Ströse, 1914; Wetzel & Rieck, 1962; Gräfner 1986; Montagut *et al.*, 1981; Peracino & Bassano, 1990) while equally rare are the alterations to the skeletal system arising from infection.

In relation to this an exception may be constituted by cases of fluorosis described in Chamois (Montagut *et al.*, 1981) and in Alpine ibex (Hars, 1990).

For this reason the need to discuss two cases of vertebral osteomyelitis observed in Chamois is held to be of some importance.

2. Personal observations

The subjects in question were two adult chamois, a 5 year old male and a 4 year old female which showed paraplegia resulting in serious difficulty in walking. The animals were captured by hand and, after a brief period of observation, were slaughtered.

Necropsy allowed us to ascertain the following:

- low nutritional state;
- presence of pneumonia foci of parasitic origin;
- the anterior mediastinic lymph nodes showed lesions which can be attributed to Pseudo-tuberculosis;
- presence of *C. tenuicollis* in the peritoneum.

In the first subject the last cervical vertebra and the first thoracic vertebra showed a purulent lesion affecting both the vertebra and the intervertebral tissue. The exudate on the hind-quarters had provoked a protuberance surround-

ded by a capsule of connective tissue.

Similarly, the medullary canal was invaded by purulent material with consequent compression of the medulla.

The pressure of the vertebra on the medulla had, in addition to the compression, provoked an "S" shaped deviation of the medulla itself (Fig. 1).

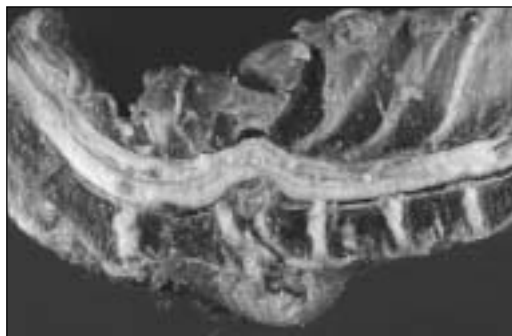

Fig. 1 - Vertebral compression and deviation of the medulla

In the second animal it was possible to note that the saggital section of the spinal column at the site of the second lumbar vertebra showed an abscess in the body of the vertebra resulting in complete modification of its architecture. At this point in the medullary canal it was possible to note a mass of whitish material which was quite solid and fibrous in texture pressing on the spinal medulla (Fig. 2).

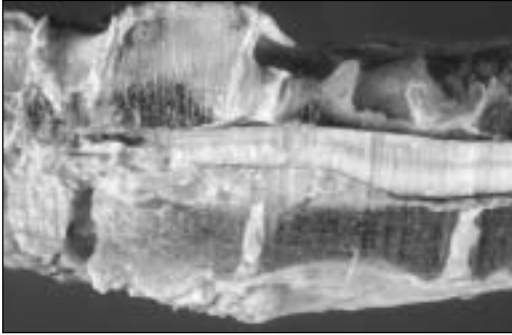


Fig. 2 - Compression of the spinal medulla

Bacteriological examination of the pathological material taken from the affected vertebra led to the isolation of a strain of *Corynebacterium pseudotuberculosis*.

3. Histopathological research

Portions of affected vertebra taken from the two chamois, after fixing with a 10% formalin buffer and decalcification, were then embedded in paraffin. The sections obtained were coloured with common methods employed in histopathology.

4. Results

Similar lesions were encountered in both animals so the pathological reports are combined in a single description.

Large sections of the vertebral bodies were replaced by proliferated fibrous connective tissue which had completely taken the place of the bone tissue. Connected with this it was possible to observe sheath-shaped purulent focus and an intense inflammation, mainly formed of neutrophilous granulocytes, for the most part in heterolysis (Fig. 3).

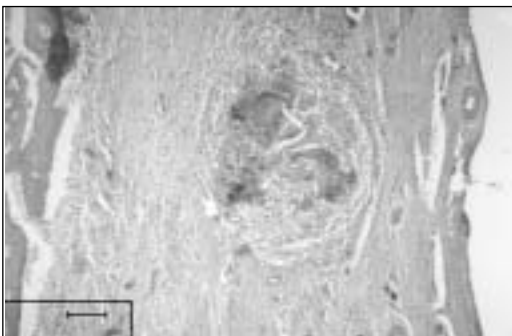


Fig. 3 - Vertebral body: purulent focus and intense inflammation (neutrophilous granulocytes)

The spinal medulla in the corresponding areas, although compressed and showing reflexive phenomena affecting the fibers, was not compromised by the inflammatory process (Fig. 4).



Fig. 4 - Deviation of the medulla: this is not compromised by the inflammatory process

5. Considerations and conclusions

The cases considered by the authors seem to be exceptional for non-domestic ruminants living in the wild as no descriptions relative to similar cases were to be found in the bibliography checked.

On the other hand it does not seem difficult to reach an etiopathogenic interpretation both on the basis of the anatomical and pathological findings or for the bacteriological result obtained from the two subjects.

The anterior mediastinic lymph nodes in fact, showed the typical alterations connected with infection by pseudotuberculosis. Pseudotubercular infection seems to be quite common, not only in sheep and goats but also in wild ruminants. This disease can progress extremely slowly, with localized forms and rarely causes the death of the affected animal. The localization of the pathogenic agent in the bone tissue can be considered to be quite exceptional. On the other hand vertebral osteomyelitis in domestic animals also does not appear to be very frequent. In addition to resulting from injury it is caused by various bacterial infections as shown in swine (Trautwein, 1960) and cattle (Diernhofer, 1938; Guarda & Cravero, 1977).

REFERENCES

- DIERNHOFER K. (1938) Zwei Fälle von Paraplegia bei kuhen sufalge Kompressionsatrophie des Rueckenmarkes. *Wiener Tier. Monat.* 25, 435.
 GRÄFNER G. (1986) - *Wildkrankheiten*, Fischer, Jena
 GUARDA F. & G.C. CRAVERO (1977) - Sulla patologia

- del midollo spinale nei bovini. *Annali Fac. Med. Vet. Torino*, 24.
- HARS J. (1990) - La Fluorose du Bouquetin des Alpes. *Atti Conv. Int. Valdieri (Italy)*, 17-19 Sept. 1987, Balbo T., De Meneghi D., Meneguz P. G. & L. Rossi (Eds.), Torino: 65-62.
- MONTAGUT G., HARS J., GIBERT Ph., PRUD'HOMME CH. and L. HUGONNET (1981) - Observations sur la pathologie des ruminants sauvages de montagne (chamois, bouquetins, mouflons) dans le departement de la Savoie du 1 Juillet 1977 an 30 Juin 1980. *Trav. Sci. Parc. nation. Vanoise*, 11, 201.
- OLT A. & A. STRÖSE (1914) - *Die Wildkrankheiten und ihre Bekämpfung*. Neumann, Neudamm.
- PERACINO V. & B. BASSANO (1990) - Traumatisme et evolution spontanee de fracture chez des chamois et bouquetins du Parc national du Grand Paradis. *Bull. Inform. Path. animaux sauvage en France*, 1987 - 1988. 5,51.
- TRAUTWEIN G. (1960) - Partielle Rückenmarks-kompression beim Schwein durch abszedierende Spondylitis. *D. T. W.* 67, 294.
- WETZEL R. & W. RIECK (1972) - *Krankheiten des Wildes*. Paul-Parey, Hamburg.